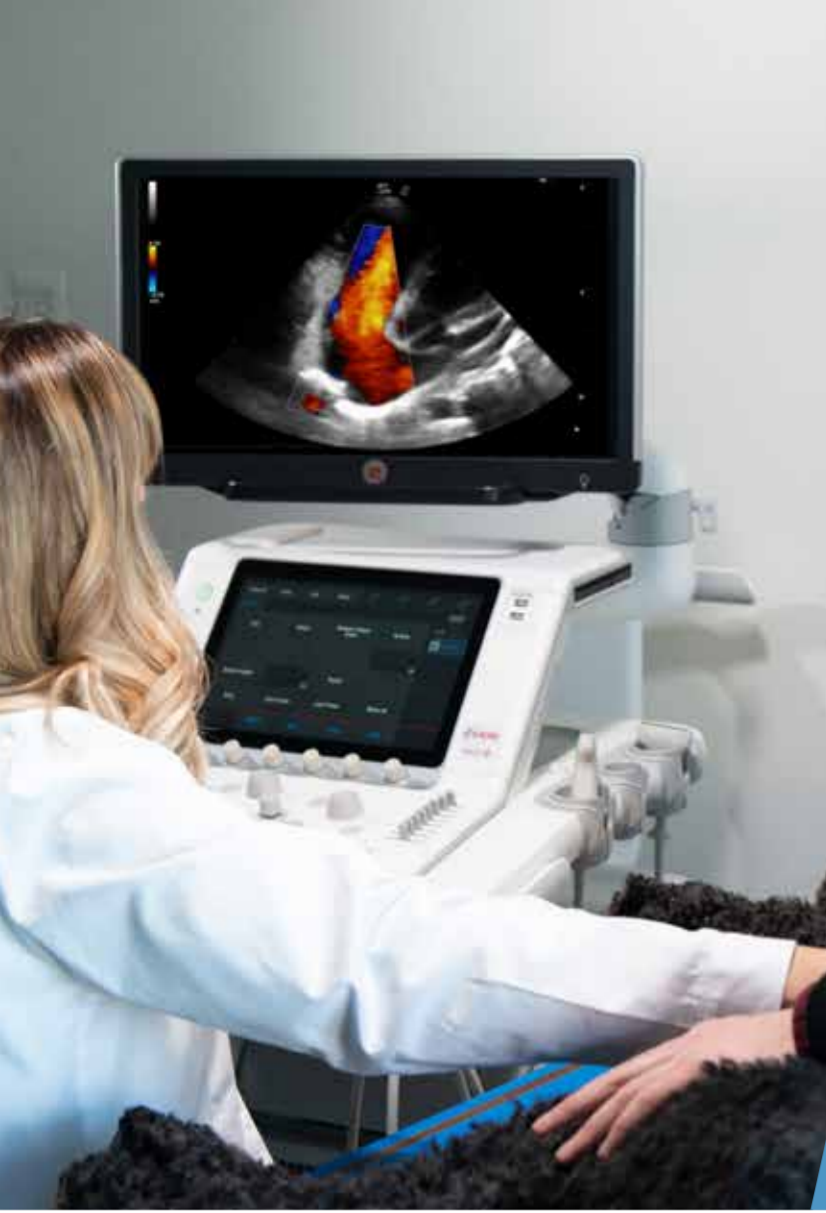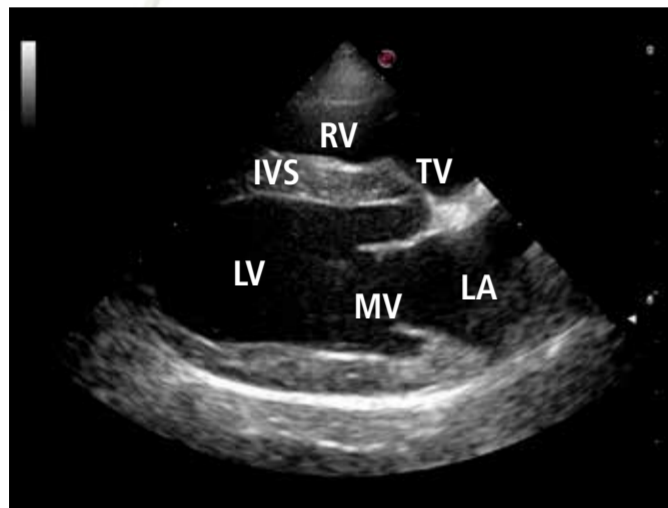
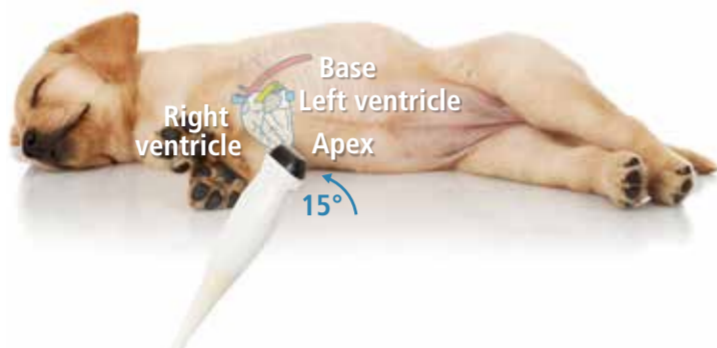
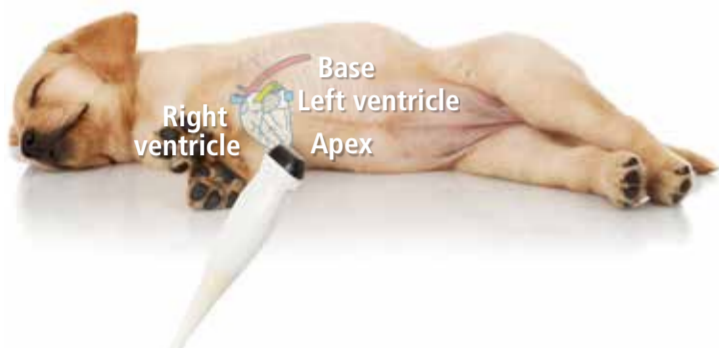
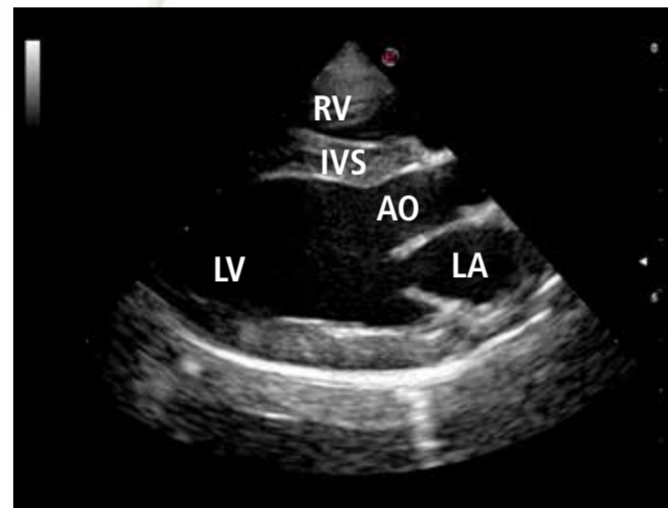




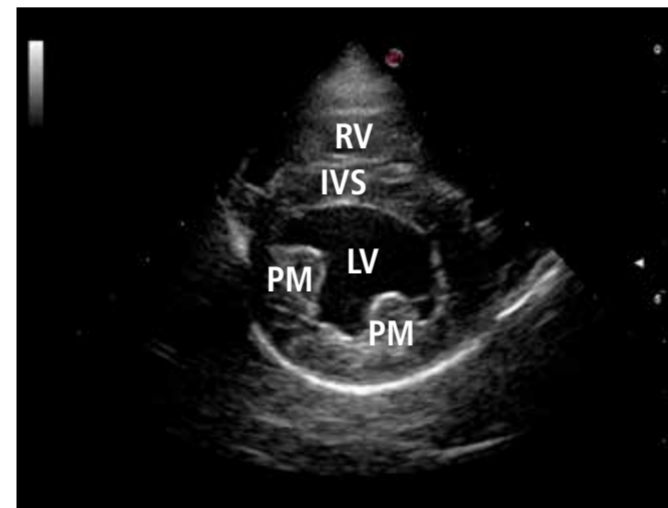
Echocardiography: **RIGHT AND LEFT PARASTERNAL WINDOW**



Right parasternal long axis view: **standard 1**

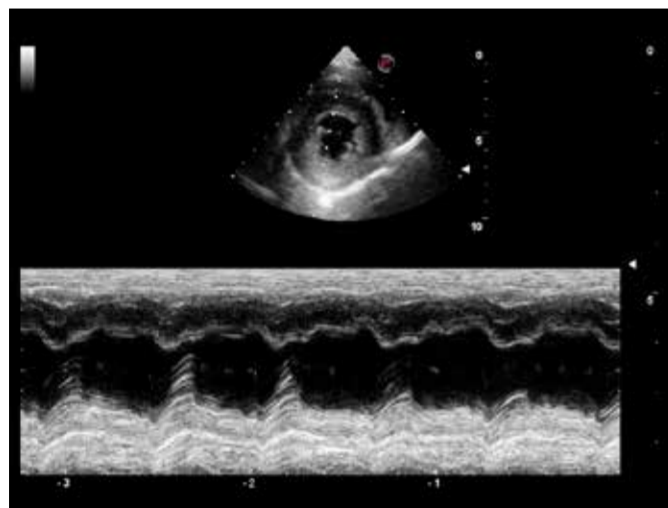


Right parasternal long axis view: **standard 2**

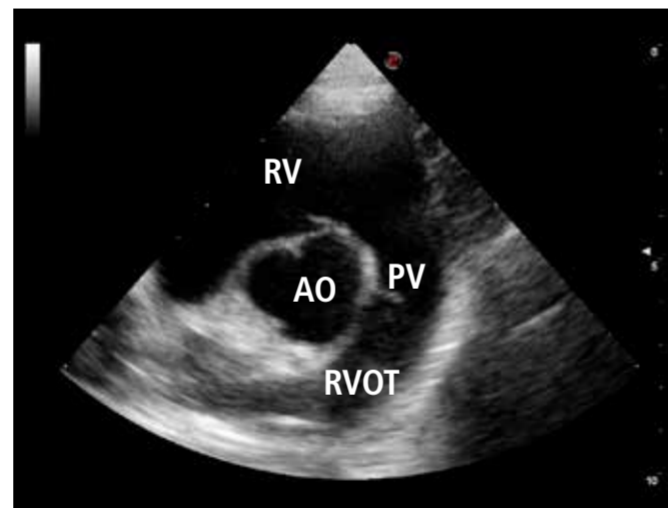


Right parasternal short axis view at the level of papillary muscles

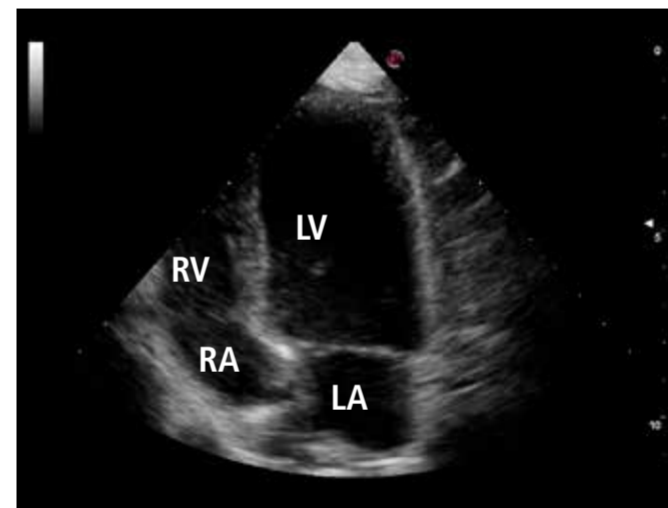
Abbreviations	
AO	Aorta
IVS	Intraventricular Septum
LA	Left Atrium
LV	Left Ventricle
MV	Mitral Valves
PM	Papillary Muscles
PV	Pulmonary Valve
RA	Right Atrium
RV	Right Ventricle
RVOT	Right Ventricular Outflow Tract
TV	Tricuspid Valves



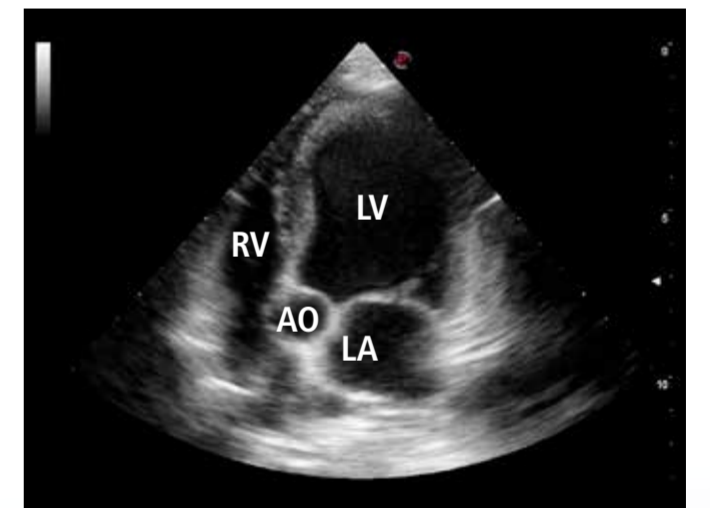
Left ventricle M-mode



Right parasternal short axis view optimized for pulmonary artery

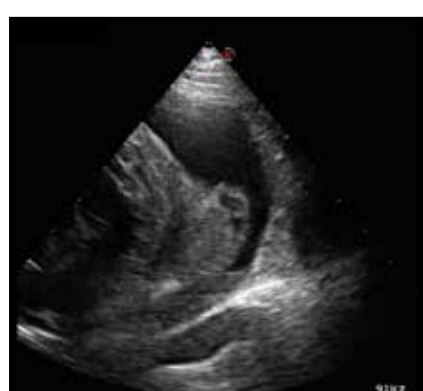

Left parasternal apical 4 chamber view

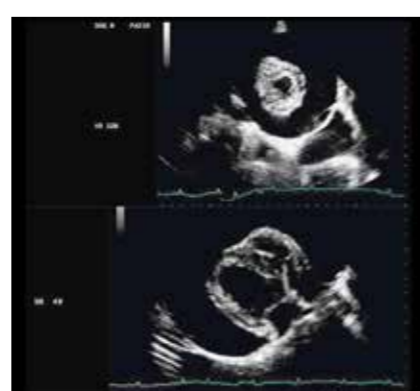

Left parasternal apical 5 chamber view

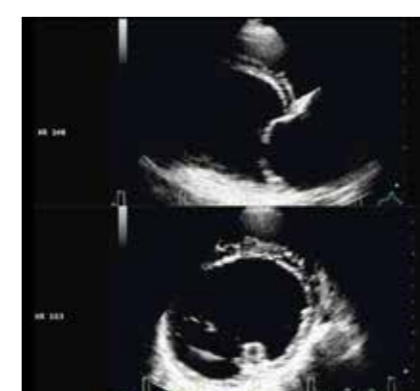Pathologies of the Heart



Hemangiosarcoma right atrial appendage
Canine



Severe pericardial effusion and cardiac tamponade
Canine



Dilated cardio myopathy
Canine